

Human Papillomavirus and P16 in the Etiology and Pathogenesis of Oropharyngeal Squamous Cell Carcinoma

Joaquín García, M.D.
Department of Laboratory Medicine and Pathology
Division of Anatomic Pathology
Mayo Clinic, Rochester, MN
USA

Objectives

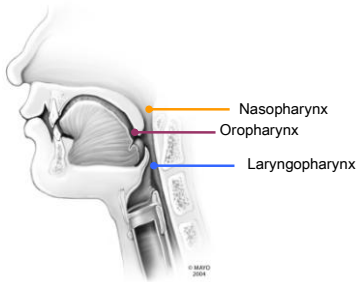
- Identify the key principles and events related to HPV in the pathogenesis of OSCC
- Recognize indications for HPV testing in OSCC
- Interpret various clinical assays designed for HPV detection in OSCC
- Understand the strengths and limitations of current assays available for HPV testing in OSCC

Outline

- I. Oropharyngeal Squamous Cell Carcinoma (OSCC) in Review
- II. The Role of Human Papillomavirus (HPV) in OSCC
- III. Indications for HPV Testing in OSCC
- IV. Interpretation of HPV Testing in OSCC
- V. HPV Testing in OSCC in Review

Oropharyngeal Squamous Cell Carcinoma in Review


Oropharynx Anatomy



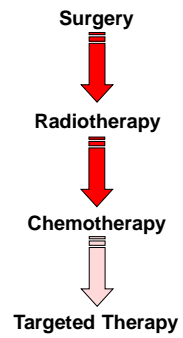
Epidemiology of OSCC — Demographics —



Epidemiology of OSCC — Incidence —

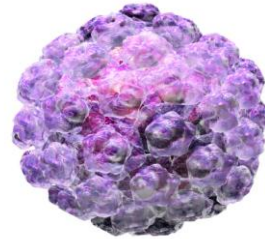


Management Strategies of OSCC

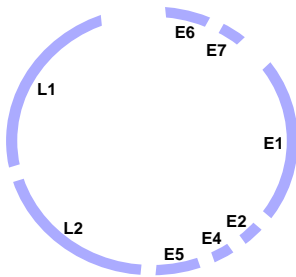


The Role of HPV in Oropharyngeal Squamous Cell Carcinoma

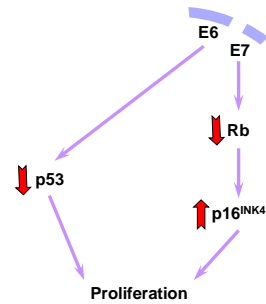
Human Papillomavirus (HPV)



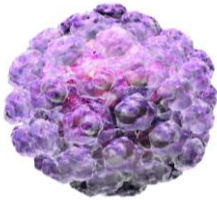
HPV in OSCC Oncogenesis — Genome —



HPV in OSCC Oncogenesis — Pathways —



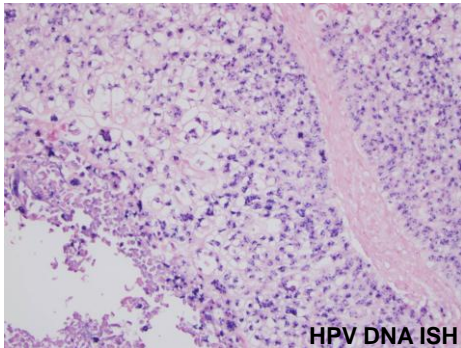
HPV in OSCC Oncogenesis — Detection —



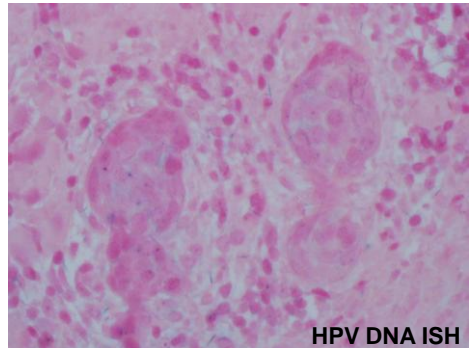
50 – 80%

Indications for HPV Testing in Oropharyngeal Squamous Cell Carcinoma

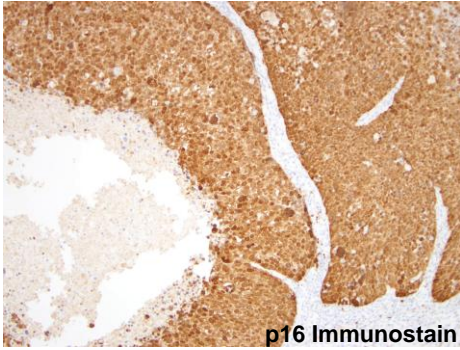
Prognostic



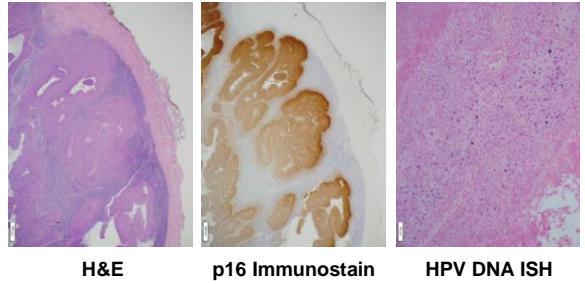
Prognostic



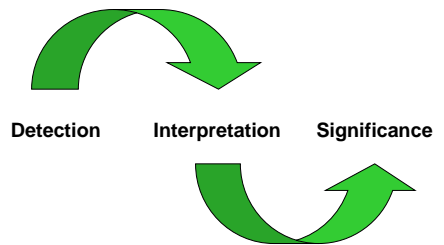
Prognostic

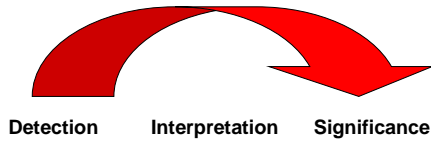


Diagnostic



Interpretation of HPV Testing in Oropharyngeal Squamous Cell Carcinoma





Polymerase Chain Reaction (PCR)

- Sensitive
- Specific
- Histologic Correlation
- Availability



DNA In Situ Hybridization

- Sensitive
- Specific
- Histologic Correlation
- Availability



E6/E7 messenger ribonucleic acid (mRNA)

- Sensitive
- Specific
- Histologic Correlation
- Availability

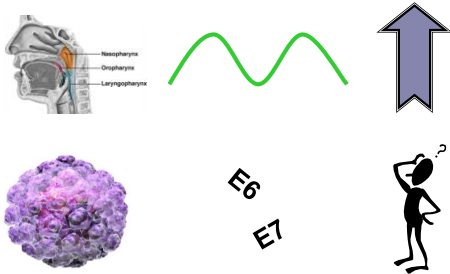


P16 Immunohistochemistry

- Sensitive
- Specific
- Histologic Correlation
- Availability



HPV Testing in Oropharyngeal Squamous Cell Carcinoma in Review



 **MAYO CLINIC**
Joaquín García, M.D.
Department of Pathology
Mayo Clinic
200 1st Street SW
Rochester, MN 55905
(507) 538-4357 (office)
(507) 284-1599 (fax)

References

1. Jo VY, Mills SE, Cathro HP, Carlson DL, Stelow EB. Low-grade sinonasal adenocarcinomas: the association with and distinction from respiratory epithelial adenomatoid hamartomas and other glandular lesions. *Am J Surg Pathol*. 2009;33:401-408.
2. Gillison ML, Koch WM, Capone RB, Spafford M, Westra WH, Wu L, Zahurak ML, Daniel RW, Viglione M, Symer DE, Shah KV, Sidransky D. Evidence for a causal association between human papillomavirus and a subset of head and neck cancers. *J Natl Cancer Inst*. 2000 May 3;92(9):709-20.
3. Lewis JS, Jr, Thorstad WL, Chenock RD, Haughey BH, Yu JH, Zhang Q, El-Mofly SK. p16 positive oropharyngeal squamous cell carcinoma: an entity with a favorable prognosis regardless of tumor HPV status. *Am J Surg Pathol*. 2010;34(8):1088-1096.
4. Ulupo OC, Flanagan JJ, Ma X, Luo Y, Thorstad WL, Lewis JS Jr. High-risk human papilloma E6/E7 mRNA detection by a novel in situ hybridization assay strongly correlates with p16 expression and patient outcomes in oropharyngeal squamous cell carcinoma. *Am J Surg Pathol*. 2011; 35(9):1343-1350.
5. Begum S, Westra WH. Basaloid squamous cell carcinoma of the head and neck is a mixed variant that can be further resolved by HPV status. *Am J Surg Pathol*. 2008; 32(7).
6. Fischer CA, Kampmann M, Zibbeck I, Green E, Tomillo L, Lugli A, Wolfensberger M, Terracciano LM. p16 expression in oropharyngeal cancer: its impact on staging and prognosis compared with the conventional clinical staging parameters. *Ann Oncol*. 2010 Oct;21(10):1961-6. Epub 2010 Apr 27.
7. Kalfou A, Cooper K. p16 (INK4a) Immunopositivity: surrogate marker of high-risk HPV and high-grade cervical intraepithelial neoplasia. *Adv Anat Pathol*. 2008 Jul;13(4):190-4.
8. Singh AD, Westra WH. Comparison of human papillomavirus in situ hybridization and p16 immunohistochemistry in the detection of human papillomavirus-associated head and neck cancer based on a prospective clinical experience. *Cancer*. 2010 May 1;116(9):2166-73.
9. El-Mofly SK, Lu DW. Prevalence of human papillomavirus type 16 DNA in squamous cell carcinoma of the palatine tonsil, and not the oral cavity, in young patients. A distinct clinicopathologic and molecular disease entity. *Am J Surg Pathol*. 2003 Nov;27(11):1463-70.

References

18. Al-Swaih JN, Huang CC, Fang FM, Chuang HC, Huang FY, Luo SD, Chen CH, Chen CM, Chen CY. Prognostic impact of p16, p53, epidermal growth factor receptor, and human papillomavirus in oropharyngeal cancer in a belt-and-robe area. *Arch Otolaryngol Head Neck Surg*. 2010 May;136(5):502-8.
19. Kreimer AR, Clifford GM, Boyle P, Franceschi S. Human papillomavirus types in head and neck squamous cell carcinomas worldwide: a systematic review. *Cancer Epidemiol Biomarkers Prev*. 2005 Feb;14(2):467-75.
20. Syrjänen S. Human papillomavirus (HPV) in head and neck cancer. *J Clin Virol*. 2005 Mar;32 Suppl 1: S59-66.
21. Gillison ML. Human papillomavirus-related diseases: oropharynx cancers and potential implications for adolescent HPV vaccination. *J Adolesc Health*. 2008 Oct;43(4 Suppl):S52-60.
22. Carpenter DH, El-Mofly SK, Lewis JS Jr. Undifferentiated carcinoma of the oropharynx: a human papillomavirus-associated tumor with a favorable prognosis. *Mod Pathol*. 2011 May 13. [Epub ahead of print]
23. Adelstein DJ, Rodriguez CP. Human papillomavirus: changing paradigms in oropharyngeal cancer. *Curr Oncol Rep*. 2010 Mar;12(2):115-20.
24. Worden FP, Ha H. Controversies in the management of oropharynx cancer. *J Natl Compr Canc Netw*. 2008 Aug;6(7):707-14.
25. St Gully J, Jacquard AC, Prétel JL, Haesebaert J, Béby-Defaux A, Clavel C, Agius G, Birembaut P, Okalski C, Léonard V, Zoubeyrat B, Prasad P, Riehmüller D, Mougin C, Denis F. Human papillomavirus genotype distribution in oropharynx and oral cavity cancer in France—The EDITH VI study. *J Clin Virol*. 2011 Jun;51(2):100-4. Epub 2011 May 6.
26. Maxwell JH, Kumar B, Fang FY, Worden FP, Lee JS, Eisbruch A, Wolf GT, Prince ME, Moyer JS, Teknos TN, Cheema DB, McHugh JB, Uitto SG, Stoerker J, Wallace HM, Kuntz DM, Cordell KG, Davis SJ, Ward PD, Bradford CR, Carey TE. Tobacco use in human papillomavirus-positive advanced oropharynx cancer patients related to increased risk of distant metastases and tumor recurrence. *Clin Cancer Res*. 2010 Feb 15;16(4):1226-35. Epub 2010 Feb 9.

References

10. Fischer CA, Zibbeck I, Green E, Probst S, Storck C, Lugli A, Tomillo L, Wolfensberger M, Terracciano LM. Is the improved prognosis of p16 positive oropharyngeal squamous cell carcinoma dependent of the treatment modality? *Int J Cancer*. 2010 Mar 1;126(5):1256-62.
11. Laborde RR, Novakova J, Olsen KD, Kasperbauer JL, Moore EJ, Smith DL. Expression profiles of viral responsive genes in oral and oropharyngeal cancers. *Eur J Cancer*. 2010 Apr;46(8):1153-8. Epub 2010 Feb 19.
12. Hafkamp HC, Speel EJM, Haesevoets A, Bot FJ, Dirjens WNM, Ramaekers FCS, Hogman AHN, Manji JJ. A subset of head and neck squamous cell carcinomas exhibits integration of HPV 16/18 DNA and overexpression of p16INK4a and p53 in the absence of mutations in p53 exons 5-8. *Int J Cancer*. 2003 Nov 15;107(3):384-400.
13. Klussmann JP, Gütthkin E, Wessendorf S, Wiestand U, Dries V, Dienes HP, Eckel HE, Pfister HJ, Fuchs PG. Expression of p16 protein identifies a distinct entity of tonsillar carcinomas associated with human papillomavirus. *Am J Pathol*. 2003 Mar;162(3):747-53.
14. Weinberger PM, Yu Z, Kountourakis P, Sasaki C, Haffty BG, Kowalski D, Merkle MA, Rimm DL, Camp RL, Piyrii A. Defining molecular phenotypes of human papillomavirus-associated oropharyngeal squamous cell carcinoma: validation of three-class hypothesis. *Otolaryngol Head Neck Surg*. 2008 Sep;141(2):382-9.
15. Cooper K, Herrington CS, Stokland JE, Evans JF, McCree J O D. Epismal and integrated human papillomavirus in cervical receptors shown by non-isotopic in situ hybridisation. *Clin Pathol*. 1991 Dec;44(12):990-6.
16. eDoctorOnline.com [2011] [photo showing regions of the human pharynx]. Medical Atlas, Atlas of Human Anatomy, Head and Neck Anatomy. Pharynx Anatomy. Retrieved from <http://www.edoctoronline.com/medical-atlas.asp?docid=23395>.
17. SOUNDPRINT Media Center [2011] [photo showing the structure of the Human Papillomavirus (HPV), used with permission of the University of Nebraska-Lincoln Angus Fox, Illustrator 2008]. HPV – The Shy Virus. Retrieved from: http://soundprint.org/radiodisplay_show/ID/774name/HPV+-the+shy+virus.

References

27. Feller L, Wood NH, Khammissa RA, Lemmer J. Human papillomavirus-mediated carcinogenesis and HPV-associated oral and oropharyngeal squamous cell carcinoma. Part 2: Human papillomavirus associated oral and oropharyngeal squamous cell carcinoma. *Head Face Med*. 2010 Jul 15;6:15.
28. Allen CT, Lewis JS Jr, El-Mofly SK, Haughey BH, Nussenbaum B. Human papillomavirus and oropharynx cancer: biology, detection and clinical implications. *Laryngoscope*. 2010 Sep;120(9):1756-72.
29. Agoston ES, Robinson SJ, Mavra KK, Birch C, Semmel D, Mirkovic J, Haddad RI, Posner MR, Kindelberger D, Krane JF, Brodsky J, Crum CP. Polymerase chain reaction detection of HPV in squamous carcinoma of the oropharynx. *Am J Clin Pathol*. 2010 Jul;134(1):26-41.
30. El-Mofly SK, Lu DW. Prevalence of high-risk human papillomavirus DNA in nonkeratinizing (cylindrical cell) carcinoma of the sinonasal tract: a distinct clinicopathologic and molecular disease entity. *Am J Surg Pathol*. 2005 Oct;29(10):1367-72.
31. Stelow EB, Jo VY, Stoler MH, Mills SE. Human papillomavirus-associated squamous cell carcinoma of the upper aerodigestive tract. *Am J Surg Pathol*. 2010 Jul;34(7):e15-24.
32. Jo VY, Mills SE, Stoler MH, Stelow EB. Papillary squamous cell carcinoma of the head and neck: frequent association with human papillomavirus infection and invasive carcinoma. *Am J Surg Pathol*. 2009 Nov;33(11):1720-4.
33. Kiyabu MT, Shibata D, Arheim N, Martin WJ, Fitzgerald PL. Detection of human papillomavirus in formalin-fixed, invasive squamous carcinomas using the polymerase chain reaction. *Am J Surg Pathol*. 1989 Mar;13(3):221-4.
34. Singh AD, Stelow EB, Mills SE, Westra WH. Lymphoepithelial-like carcinoma of the oropharynx: a morphologic variant of HPV-related head and neck carcinoma. *Am J Surg Pathol*. 2010 Jun;34(6):890-5.
35. Perrone F, Ghogni A, Corbellazzi B, Bossi P, Licita L, Pilotti S. Isolating p16-positive/HPV-negative oropharyngeal cancer: an effort worth making. Comment on Am J Surg Pathol. 2010 Aug;34(8):1088-96. *Am J Surg Pathol*. 2011 May;35(5):774-7. author reply 777-8.